

Livestock Health Series

Sore Mouth in Sheep and Goats

Chelsey Kimbrough, Ph.D.
Associate Professor

Heidi Ward - DVM, Ph.D.
Assistant Professor and
Veterinarian

Introduction

Contagious ecthyma, commonly known as sore mouth or orf, is a highly contagious virus commonly seen in young lambs, kids and nursing dams. Some strains are more severe than others but typically run their course within four weeks. Sore mouth is zoonotic meaning it can be transmitted to humans. A scab-like lesion on lambs and kids can be seen on the lips, around the mouth, nostrils, and eyes. Furthermore, lesions can be present on nursing dams on their teats, udders, legs and sometimes vulvas. When dried scabs fall off, the virus can still be active within the scab and has the ability to survive up to a year becoming a source for later infections.

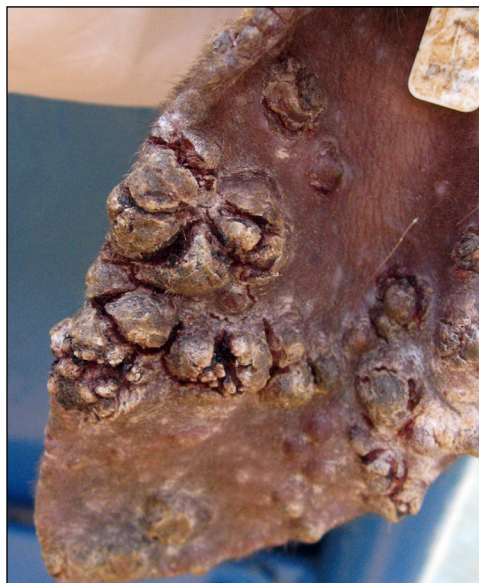

Photo 1. Lesions present on an ear. Source: Susan Schoenian

Signs and Symptoms

Tiny red nodules around the lips are the first signs of sore mouth. The nodules develop into blisters and then form a thick, brown scab. If the scab is removed, red wart-like tissue will be seen. If the scab is not removed, it will naturally fall off. The process may take as long as four weeks. If severely infected, animals often stop eating due to pain from the lesions.




Photo 2. Sore mouth presenting in the lip corner of a goat. Source: Susan Schoenian

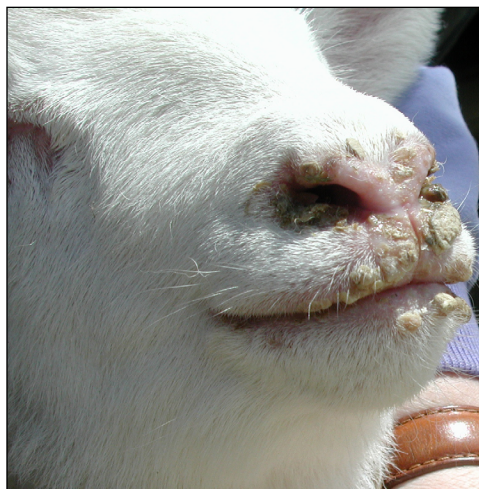


Photo 3. Orf lesions on a lamb's nose and lips. Source: Susan Schoenian

*Arkansas Is
Our Campus*

Visit our web site at:
<https://www.uaex.uada.edu>

Infected lambs and kids can transmit the virus to their dams. Due to the subsequent painful teat and/or udder lesions, dams often do not allow the lamb or kid to nurse. Furthermore, the infected dams are at risk of developing mastitis due to a secondary bacterial infection. Lambs and kids may need to be supplemented to ensure their nutritional needs are being met. Sore mouth can mimic other vesicular type diseases such as vesicular stomatitis or foot and mouth disease. If several animals are affected in the herd or flock, it is recommended a veterinarian confirm the disease.

Treatment and Prevention

Affected animals should be isolated to prevent sore mouth spreading through the flock or herd. Although there is no treatment for the viral infection, the lesions can be treated with iodine or chlorhexidine to prevent secondary bacterial infection. It is important to wear gloves when treating sore mouth as it can be transmitted to humans. If a person suspects they have been exposed, he or she should seek medical attention. Once scabs have fallen off, sheep and goats should be monitored until wounds completely heal to ensure secondary bacterial infections do not occur.

Vaccines are available for sheep and goats and may be appropriate in flocks or herds having severe and frequent outbreaks. Vaccines are usually only recommended for use on farms where the disease has occurred. Typically, only healthy animals should be vaccinated, but research studies have shown that in outbreaks of sore mouth, vaccination may shorten the course of disease.

The vaccine is a live virus vaccine which requires extra precautions. Gloves should be worn when handling the vaccine. The scab that falls off from the vaccine injection site on the animal contains a viable virus which can introduce

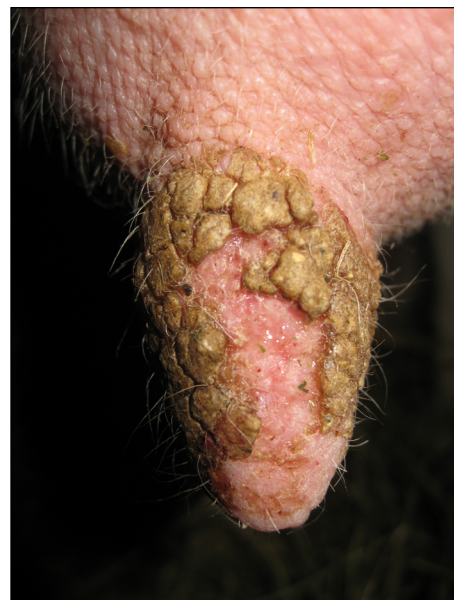

Photo 4. Lesions present on a teat. *Source: Susan Schoenian*

sore mouth into your flock or herd. Once the vaccine has been used on your operation, it may be necessary to vaccinate yearly to prevent further outbreaks. It is important to consult with a veterinarian to make a thorough decision on a sore mouth vaccination protocol.

Good biosecurity practices should be followed to help with prevention of sore mouth, especially when introducing new animals into the flock or herd or if animals are used for exhibition.